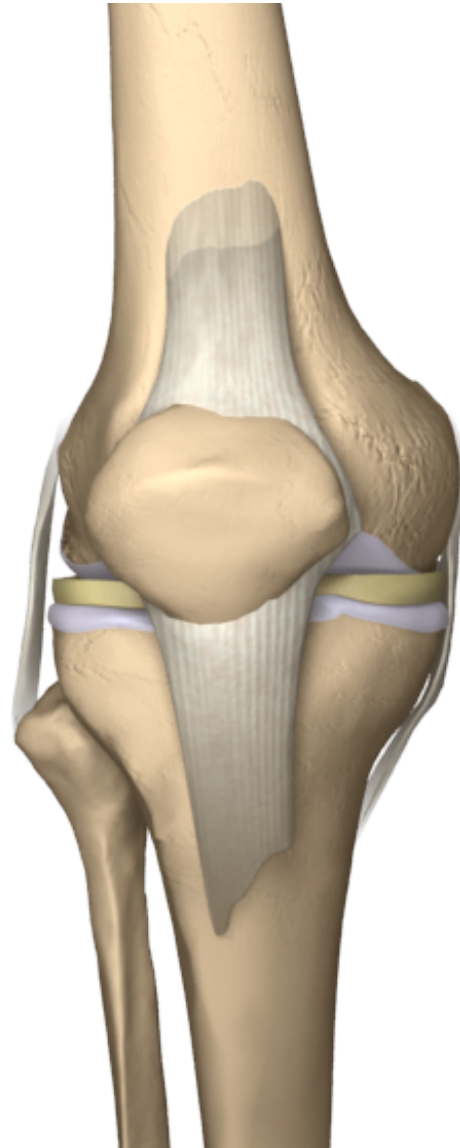
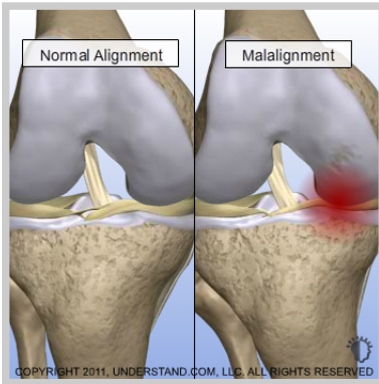


# High Tibial Osteotomy

With each step, forces equal to three to eight times your body weight travel between the thigh bone (femur) and shin bone (tibia) in your knee. These forces are dampened by a meniscus on the inner and outer portion of the knee, and the ends of the bones are protected by articular cartilage. Patients with a condition known as osteoarthritis, or degenerative arthritis, experience a successive wearing on the menisci and articular cartilage, which may abrade or develop tears. These degenerative processes limit the ability of the knee to glide smoothly and can result in popping, catching, locking, clicking and pain. In a condition called malalignment, unbalanced forces cause excessive pressure on either in the inner (medial) or outer (lateral) portion of the knee.



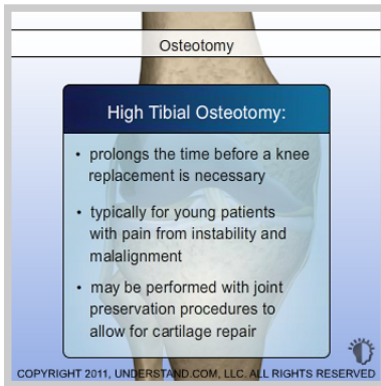


### ***High Tibial Osteotomy Introduction***

With each step, forces equal to three to eight times your body weight travel between the thigh bone (femur) and shin bone (tibia) in your knee. These forces are dampened by a meniscus on the inner and outer portion of the knee, and the ends of the bones are protected by articular cartilage. Patients with a condition known as osteoarthritis, or degenerative arthritis, experience a successive wearing on the menisci and articular cartilage, which may abrade or develop tears. These degenerative processes limit the ability of the knee to glide smoothly and can result in popping, catching, locking, clicking and pain. In a condition called malalignment, unbalanced forces cause excessive pressure on either in the inner (medial) or outer (lateral) portion of the knee.

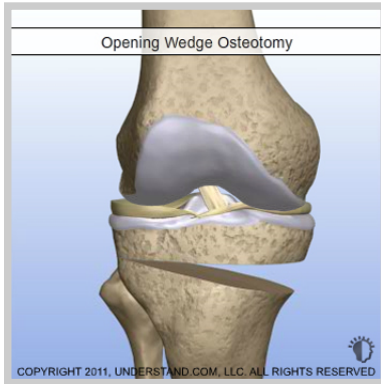#### **Doctor's Personal Note: A Message From Dr. Pevny**

*Thank you for visiting my website and viewing the 3D Animation Library. These animations should assist you in better understanding your condition or procedure. I look forward to answering any additional questions you may have. Please make an appointment by calling (970) 544-1289.*



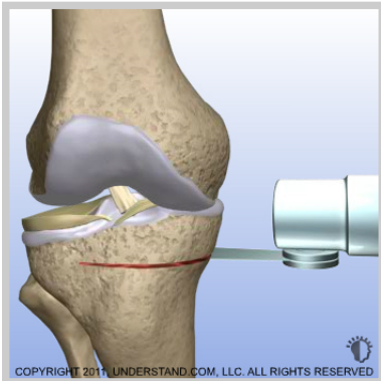
### ***When the Procedure is Performed***

Degenerative arthritis and malalignment can cause the knee's protective tissues to wear on one side more than the other in a repetitive cycle of damage. A partial or total knee replacement can correct this condition when joint damage is beyond repair. In certain cases, however, a technique known as an osteotomy can realign the knee, taking pressure off the damaged side. A procedure known as a high tibial osteotomy wedges open the upper shin bone (tibia) to reconfigure the knee joint. The weight-bearing part of the knee is shifted from degenerative or worn tissue onto healthier tissue. A high tibial osteotomy is generally considered a method of prolonging the time before a knee replacement is necessary because the benefits typically fade after eight to ten years. This procedure is typically reserved for younger patients with pain resulting from instability and malalignment. An osteotomy may also be performed in conjunction with other joint preservation procedures in order to allow for cartilage repair tissue to grow without being subjected to excessive pressure.



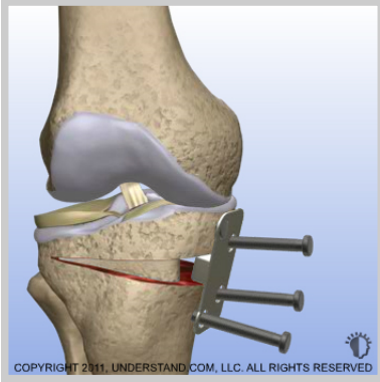
### ***Procedure Variations***

Osteotomy procedures can be done to correct either a bowlegged (varus deformity) or knock-kneed (valgus deformity) malalignment. There are a variety of procedures to correct these conditions, which differ in the manner and position in which the bone is cut or shaped. In what is called an opening wedge osteotomy, a cut is made in the shin bone and a bone graft and instrumentation are used to hold the wedge open and realign the knee. In a closing wedge osteotomy, a wedge of bone is removed from the tibia, the gap is closed, and the edges are fastened together for the realignment. Other variations of osteotomies performed in the knee may involve the thigh bone (femur) or may be done to realign the knee cap (patella). This animation will show a repair of the more common bowlegged deformity by means of the opening wedge technique. This procedure realigns the knee, which alleviates pain and reduces the forces damaging the inside (medial) part of the knee.



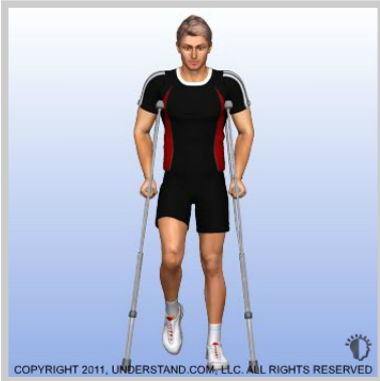### ***Incisions and Wedge Creation***

An incision is made along the inner portion of the knee, allowing the surgeon to access the shin bone (tibia). A cut is made with a specialized saw to create a gap and the two sides of the bone are separated, creating a wedge-shaped opening. The amount of opening is predetermined in your surgeon's office based on X-rays taken to determine the optimal alignment.



### ***Repair***

After the wedge has been created, a piece of bone graft is either harvested from the iliac crest of the pelvis, or a bone graft substitute is added to the gap to hold open the space and realign the knee. Next a stainless steel or titanium plate and screws are used to hold the bone graft in position, and the plate is fastened with screws on each side of the wedge.



### ***End of Procedure***

After the plate and screws are secured, all surgical instruments are removed, the incisions are closed, and the procedure is completed. An osteotomy is occasionally performed as an outpatient procedure, but most patients will remain in the hospital for a day or two. Most patients are placed in a brace and range of motion exercises will begin according to your surgeon's plans. Your specific recovery plan will be determined by your surgeon depending on any other procedures that were done at the same time. Typically crutches are used for at least 6 weeks and full weight bearing can be expected by 8 weeks.