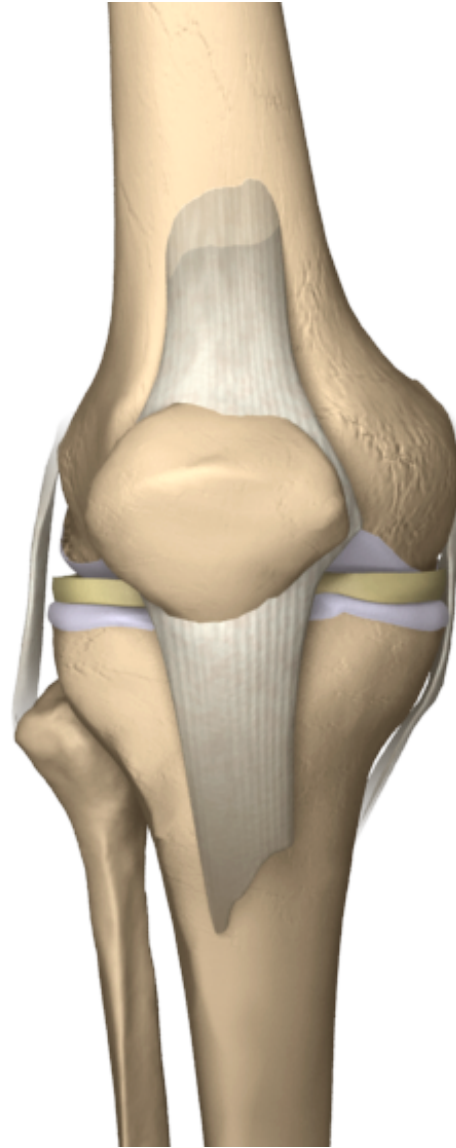
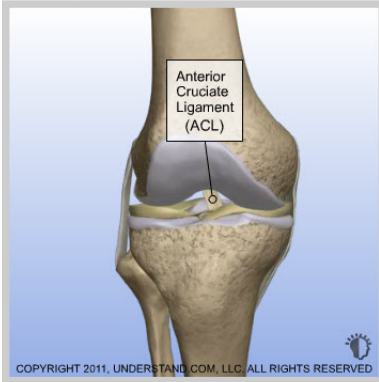

Torn ACL - Anatomic Footprint ACL Reconstruction

The anterior cruciate ligament (ACL) is one of four ligaments that are crucial to the stability of your knee. It is a strong fibrous tissue that connects the femur to the tibia. A partial or complete tear of your ACL will cause your knee to become less stable and feel as though your knee is about to give out. There are a number of different graft options to replace your torn ACL. Your surgeon will select the option that is best for you.



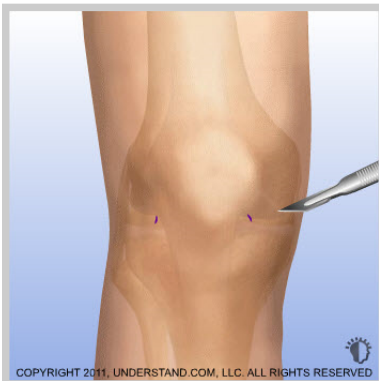

Introduction

The anterior cruciate ligament (ACL) is one of four ligaments that are crucial to the stability of your knee. It is a strong fibrous tissue that connects the femur to the tibia. A partial or complete tear of your ACL will cause your knee to become less stable and feel as though your knee is about to give out. There are a number of different graft options to replace your torn ACL. Your surgeon will select the option that is best for you.

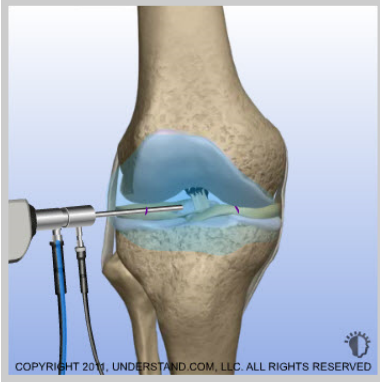Doctor's Personal Note: A Message From Dr. Pevny

Thank you for visiting my website and viewing the 3D Animation Library. These animations should assist you in better understanding your condition or procedure. I look forward to answering any additional questions you may have. Please make an appointment by calling (970) 544-1289.



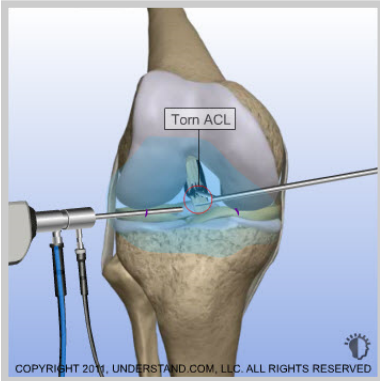
Incisions

Small incisions (portals) are made around the joint. The scope and surgical instruments will go into these incisions.



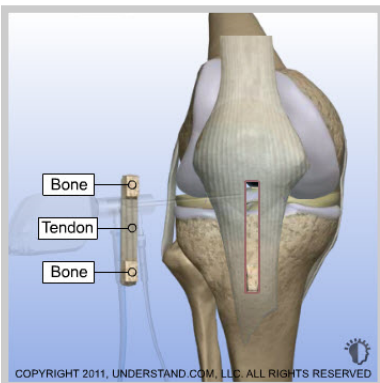
Visualization

The scope is inserted into the knee. Saline solution flows through a tube (cannula) and into the knee to expand the joint and to improve visualization. The image is sent to a video monitor where the surgeon can see inside the joint.



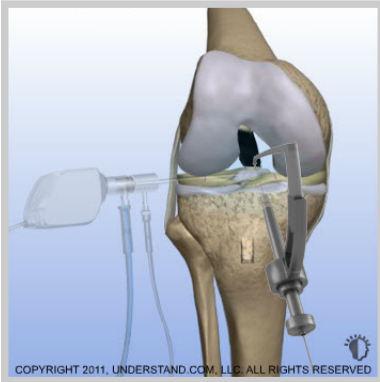
Diagnostic Arthroscopy

Meticulous diagnostic arthroscopy is performed to evaluate the structures surrounding the torn ACL, including the meniscal cartilage and the articular cartilage. Any lesions of either of these structures are repaired. This is critical to achieve full function.



Graft Harvest

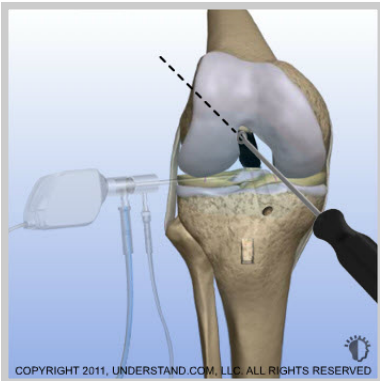
Every attempt is made to make the most cosmetic incision possible for harvesting the graft material. For example, an incision of about 40mm is made to obtain an 85 mm graft. The central portion of the patellar tendon is removed using a scalpel and motorized tool. The ends of the tendon are attached to plugs of bone from your patella and tibia. These plugs of bone will help anchor what will become your new ACL.



Tibia Preparation

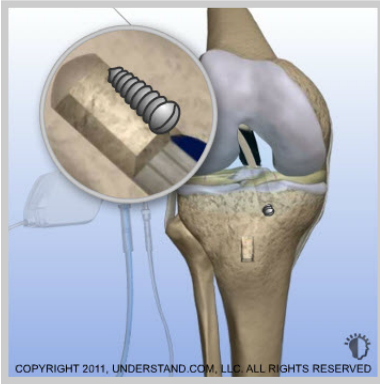
Identification of the insertion points for the ACL on the femur and tibia is then performed to match the exact ACL anatomy of the patient.

The center of the insertion point on the tibia is precisely identified and marked with an awl. A tibial aiming guide is then inserted which allows a surgeon to pass a guide wire from the tibial surface into the precise center of the tibial ACL insertion point. The guide wire is positioned to reproduce the precise position of the insertion point and also the precise angle of the ACL based on the existing ACL fibers. Once the final position and angle are achieved, the tibial tunnel is reamed over the guide wire.



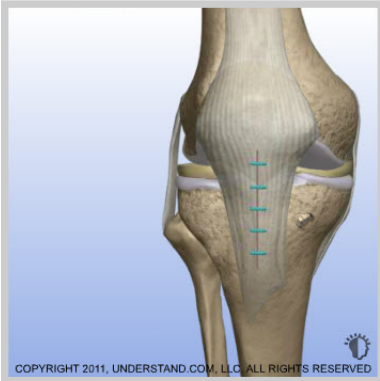Femur Preparation and Graft Insertion

The center of the femoral insertion point is then identified and marked with an awl. A femoral aiming guide is inserted through one of the portals. This allows a flexible guide wire to be placed in the exact position and at the correct angle. A flexible reamer is passed over the guide wire and the tunnel is created in the femur. The end of the graft is tied to a loop on the guide wire and the graft is pulled into place.



Securing the Graft

Screws are used to secure the plugs of bone into the tunnels. Over time, the plugs of bone will incorporate into the surrounding bone.



End of Procedure

With the new ACL in position and secured, the surgical instruments are removed and the procedure is completed.